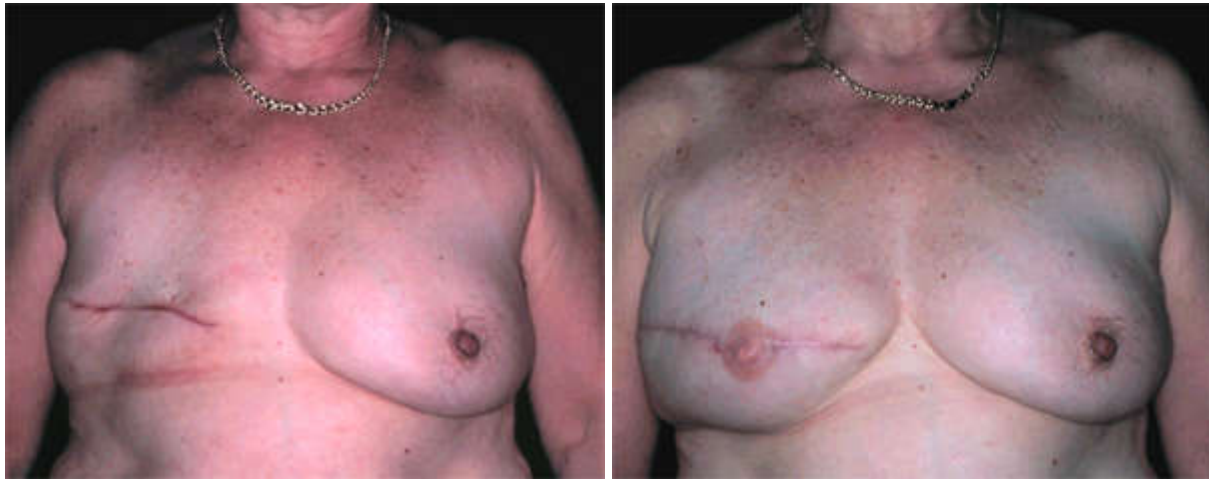

VCH Breast Reconstruction Program

Before and After Photos

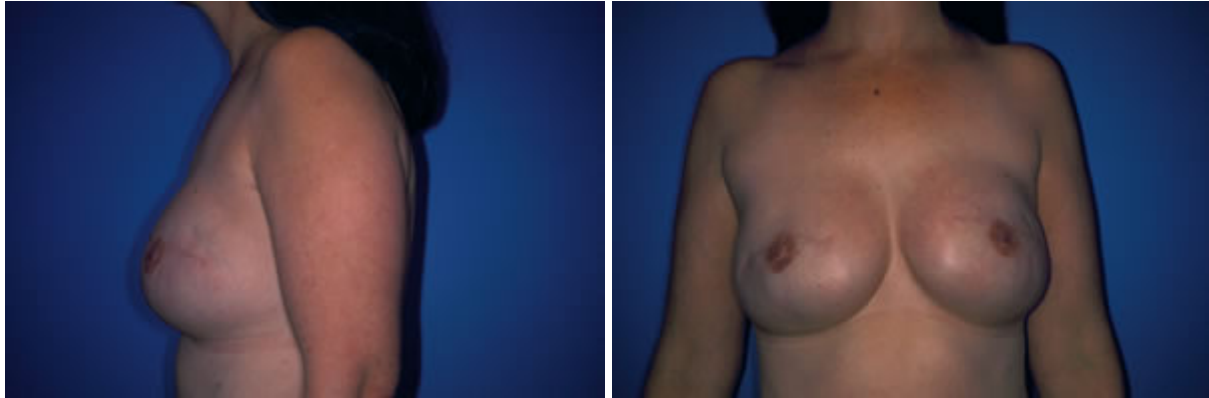
Before and After Photos of Tissue Expander Procedure

This patient previously had a right mastectomy and delayed tissue expander surgery. No surgery was required to the opposite breast as its shape matched the reconstructed breast. Approximately four months after placement of the tissue expander, the device was removed and replaced with a permanent implant. At this time the nipple was made and the areola was tattooed later.



After Photos of Silicone Gel Implants

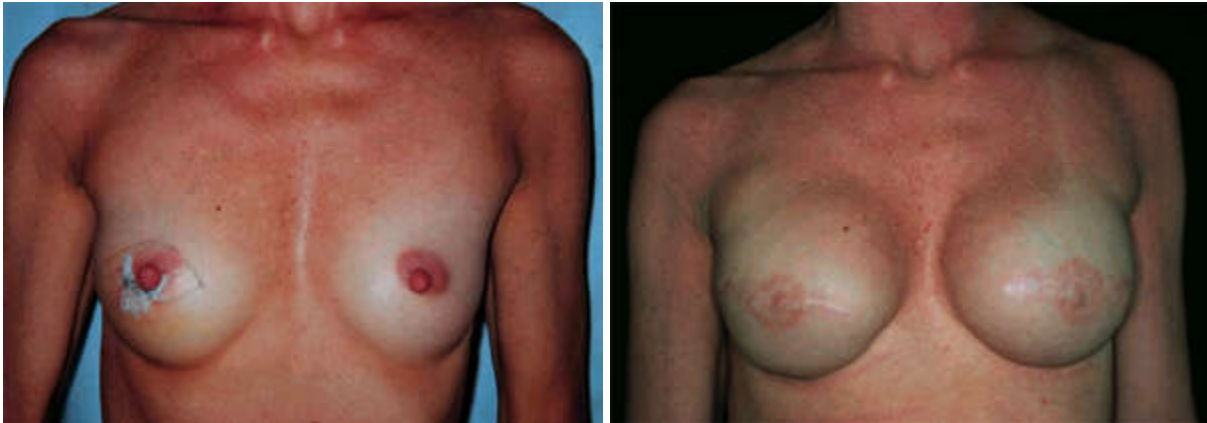This patient had silicone gel implants after a tissue expander procedure.



Before and After Photos Saline of Implant

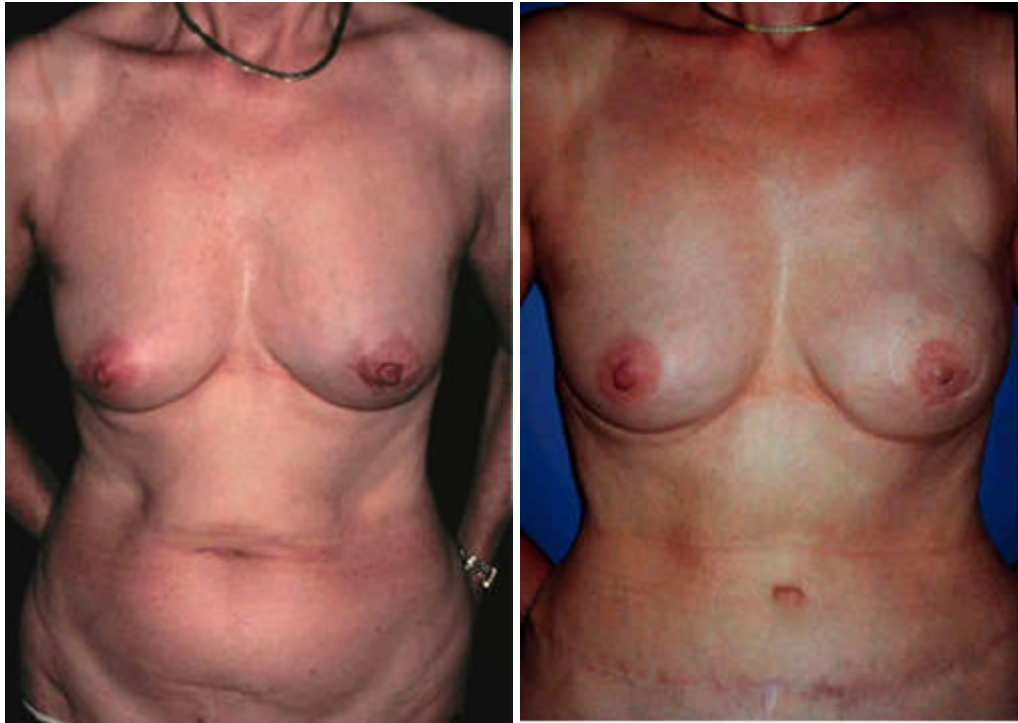This patient had bilateral (both breasts) mastectomies and immediate reconstruction with tissue expanders. The expanders were inflated to a size larger than the patient's pre-operative status (patient's choice).

The tissue expanders were replaced with permanent implants about 4 months later, at which time bilateral nipples were reconstructed using tissue from the reconstructed breast mound. The areolas were tattooed later.



Before and After Photos of Immediate TRAM Flap Procedure (Pedicle)

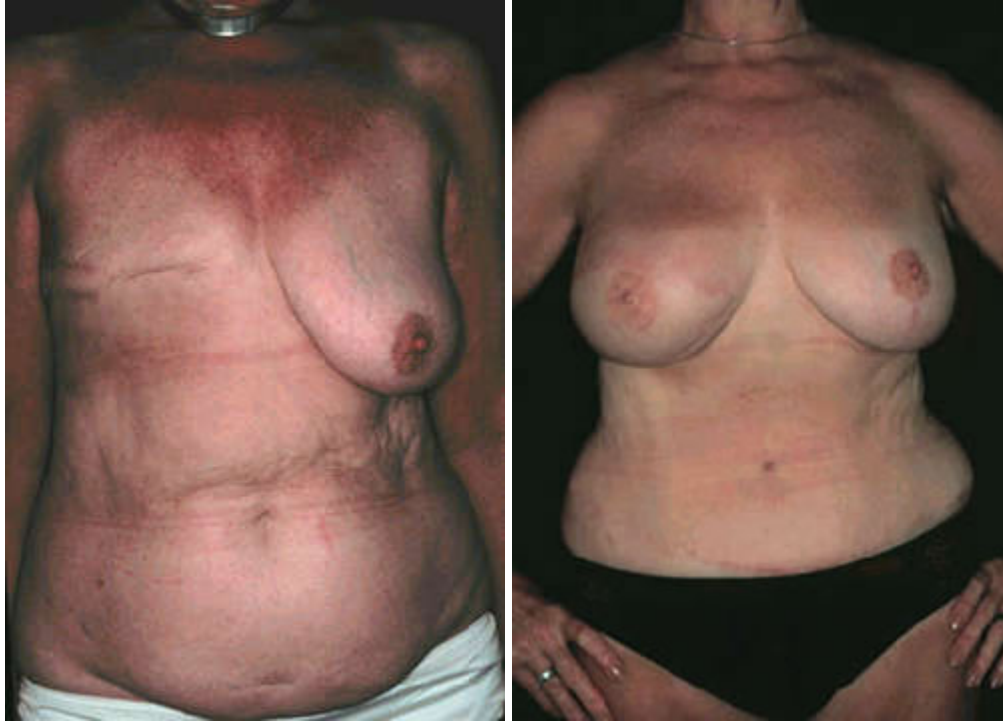This patient had immediate left TRAM flap breast reconstruction at the same time as the mastectomy surgery. The mastectomy was done through a skin sparing method. This method optimizes the overall aesthetic outcome and is one of the major advantages of immediate breast reconstruction. Most slender and even fit women have some excess abdominal tissue, which can be used to reconstruct a breast.



This patient subsequently had a left nipple reconstruction with local flap and areola tattooing

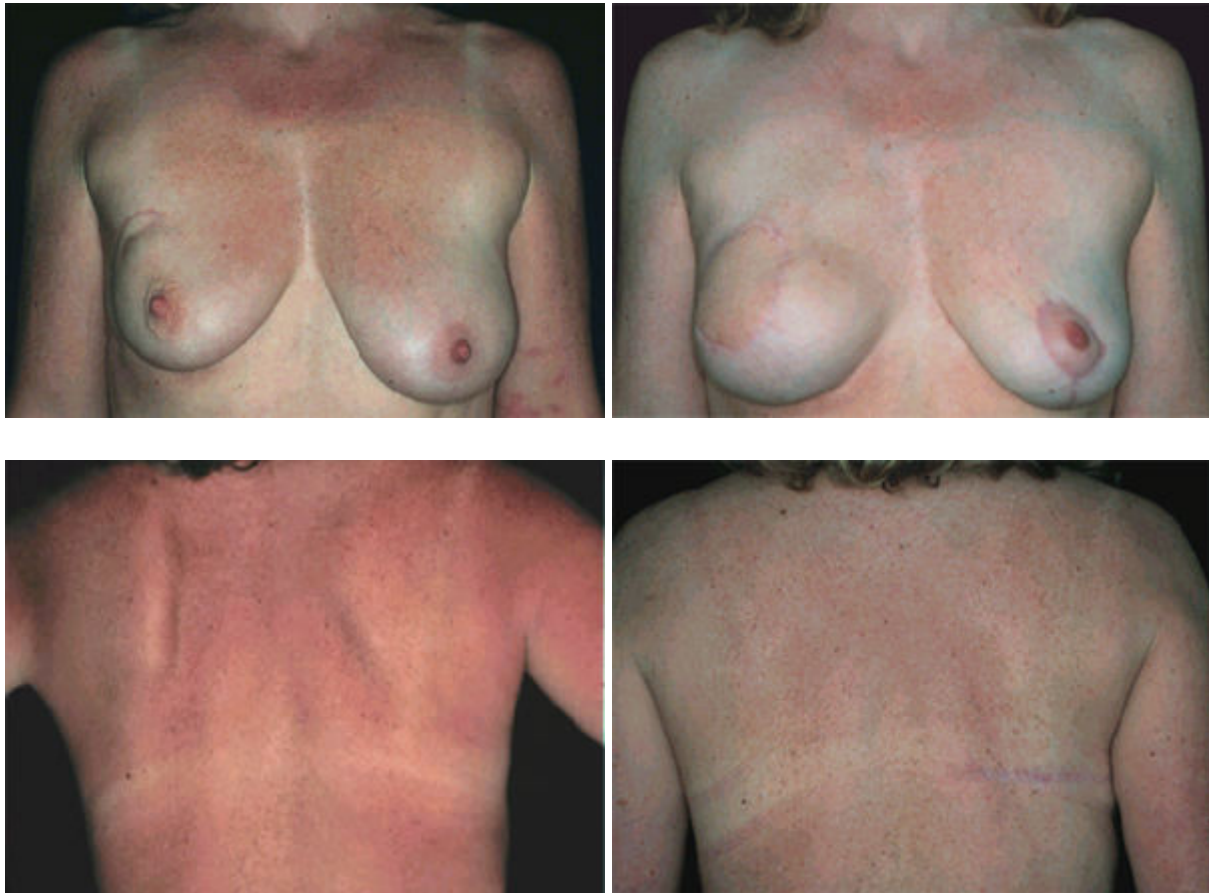Before and After Photos of Delayed TRAM Flap and Breast Reduction (Pedicle)

This patient had previously had a right mastectomy and decided to have breast reconstruction using her abdominal tissue (TRAM flap).



Before and After Photos of Latissimus Dorsi Procedure

This patient had previous breast cancer, which was treated with breast conservation treatment (lumpectomy and radiation). She developed recurrence and required a mastectomy. She chose immediate reconstruction but was not a good candidate for TRAM flap reconstruction. Also because of the previous radiation, it was felt a better result could be achieved with a latissimus dorsi flap. A small saline implant was used in combination with the latissimus flap to match the size of her breasts. The early post-operative result prior to nipple reconstruction is shown, as is the donor site scar on the back.



Nipple Reconstruction Photographs

NOTE: While the photos of the different nipple reconstruction procedures may upset some people, the intent is to inform women who are in the process of making a decision about whether to undergo breast reconstruction.

This patient had an immediate right TRAM flap reconstruction, nipple reconstruction and areolar tattoo.

