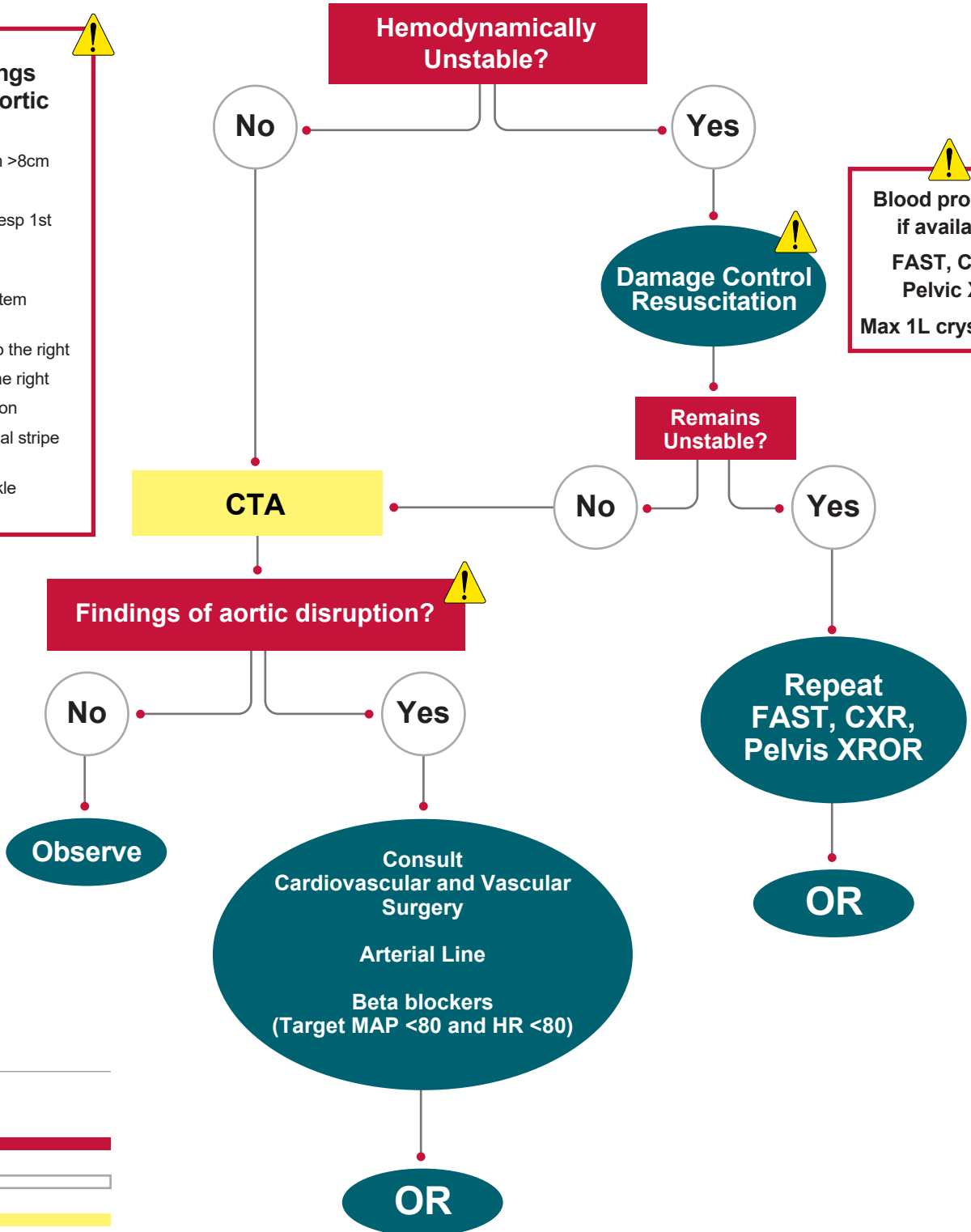


Thoracic Aortic Blunt Trauma (Suspected)

- Diagnostic findings suspicious for aortic disruption**
- Widened mediastinum >8cm
 - Left Hemothorax
 - Multiple rib fractures (esp 1st and 2nd ribs)
 - Apical Cap
 - Depressed left main stem bronchus
 - Deviation of trachea to the right
 - Deviation of NGT to the right
 - AP window opacification
 - Paratracheal/paraspinal stripe widening
 - Obscured aortic knuckle

- Blood products if available**
- FAST, CXR, Pelvic XR
- Max 1L crystalloid



LEGEND

Decision Point	
Selection	
Diagnostic Step	
Action Item	